INTRACRANIAL GERM CELL TUMORS, THE EXPERIENCE OF THE ALGIERS UNIVERSITY HOSPITAL AND A LITERATURE REVIEW

DJ. DAOU, Y. FELISSI, A. MORSLI

Neurosurgery
Department, Mohamed Lamine Debaghine University hospital
Bab -El-Oued – Algiers -Algeria

ABSTRACT ***Purpose*** **:** Primary intracranial germinomas (PIGs) are rare malignant brain tumors that represent approximately 0.2% to 1.7% of all primary intracranial tumors. In this study, clinical outcomes of thirteen consecutive PIGs have been presented in hospital university of Algiers and a literature review. ***Material and Methods :*** Thirteen patients were treated from 1999 to 2020 for histologically verified primary intracranial germinoma. Median age was 22 years (range:17 months–42 years). Most of patients were males and received only radiotherapy after surgery. ***Results*** : seven patients were in complete remission, three of them died by surgical and endocrine complications, one patient had recurrence two years after complete remission. One patient died after radiotherapy. ***Conclusion*** : PIG is a mostly malignant tumors. They are radiosensitive tumors. Subtotal or near-total resection using stereotactic guide or direct surgery to confirm the histopathological diagnosis followed by chemotherapy and radiotherapy rather than GTR is therefore the treatment of choice.

Keywords : Primary intracranial germinoma, Pineal gland, Suprasellar region, Radiotherapy, Drop metastasis.

INTRODUCTION

Primary intracranial germinoma (PIGS) are rare malignant lesions that mostly occur in brain midline regions, they are the most frequent germ all cerebral tumors (60-70 %). They occur in the first two decades of life. PIGS are more common in male than females. Pineal gland and suprasellar region are the most frequents sites of central nervous germinomas.

The clinical presentation depends on the location of the tumor. Due to their rarity, most of the published series relate to a few PIGS cases, especially those coming from Africa.

This is a retrospective analysis of 13 cases of PIGS to report our experience in the management of CNS germinomas and literature analysis.

MATERIAL AND METHODS

We reviewed retrospectively 13 cases of histopathologically confirmed germinomas who were operated in our department of neurosurgery between 1999 and 2020.

The clinical outcomes were evaluated retrospectively using patient's complaints, the period between the first complaint and surgery, localization, serum and cerebrospinal fluid levels of tumor markers, recurrence rate and complications, Standardized follow-up was carried out in all survival patients in our study. Full neurological examination and contrast-enhanced craniospinal magnetic resonance imaging (MRI) were performed one month after the treatment (surgical intervention+ RT +/- chemotherapy). Then, every three months, the patients were examined neurologically. If there was no complaint, contrast-enhanced craniospinal MRI was performed every six months.

ILLUSTRATIVE CASES

CASE 1 :

Twenty (20) year old male with diabetes insipidus, pan hypopituitarism, bitemporal hemianopsia.

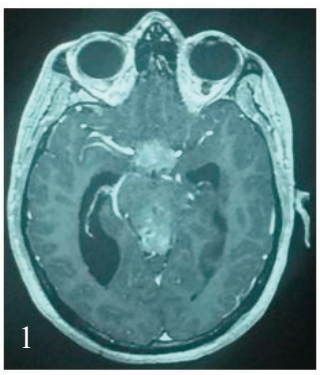

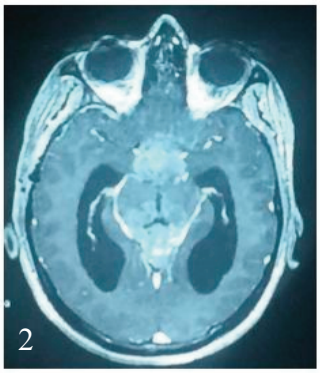

Fig. 1: Preoperative axial contrast enhanced MRI that shows double location of tumor in suprasellar and pineal.

Fig. 2 : post-operative axial contrast enhanced MRI that shows approximatively the same aspect before surgery (the patient had a biopsy, that was histologically in favor of germinoma).

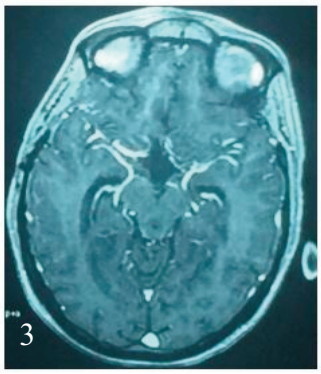

Fig. 3: post radiotherapy axial contrast enhancement MRI shows complete remission after RT (45 gray), No recurrence or residual tumor.

CASE 2 :

Twenty fort (24) year male, with headache + vomiting

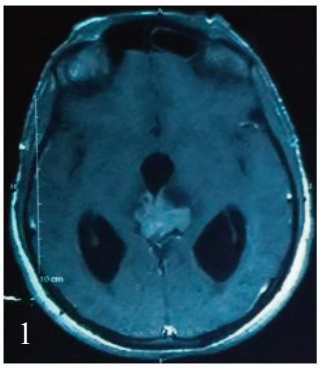

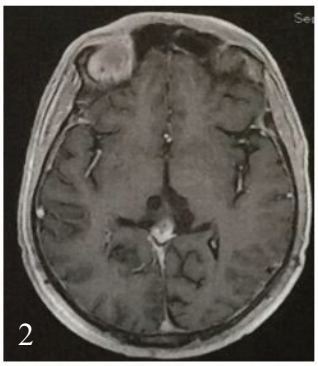

Fig. 1: Preoperative axial contrast enhanced MRI that shows pineal tumor +hydrocephalus

Fig. 2 : post-operative axial contrast enhanced MRI that shows a residue of pineal tumor (STR through sub occipital trans tentorial approach).

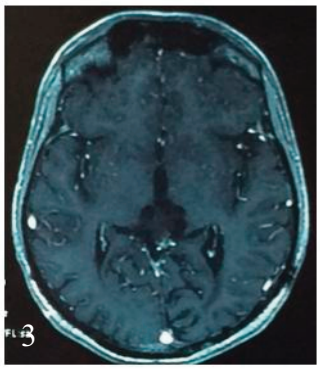

Fig. 3: post radiotherapy axial contrast enhancement MRI shows complete remission after RT (45gray). No recurrence or residual tumor.

RESULTS

Almost all patients were males, and adults, the only female in our series was a child of 17 months. The mean age was 22 years. The most common complaints were diabetes insipidus, endocrine deficiency (pan hypopituitarism) which is followed by headache and vomiting, then decreased visual acuity and bilateral papillary edema in 3 cases, diplopia and parinaud's syndrome in two cases, finally : bilateral hemianopsia generalized seizure, hemiparesis, aphasia, were noticed at once (Table I).

The duration between the initial symptom and time of surgical intervention ranged between 15 days and 26 months. Seven patients had obstructive hydrocephalus, two patients had ventriculo-cisternostomy + biopsy, two patients had stereotaxic biopsy, Five patients had VP shunt before STR through microsurgical approachs (supracerebellar infratentorial approach, sub-occipital trans tentorial, trans lamina terminalis (V3), trans cortical trans ventricular, trans callosal approach).

Three patients died after surgery related to surgical complications. One died after the beginning of radiotherapy because of endocrine complications .all the patients who survived after surgery (ten patients) had radiotherapy, only two of them had chemotherapy + radiotherapy, eight patients had complete remission, and no recurrence of the tumor have been noticed until now. Recurrence and drop metastases have been observed in one case with a double location germinoma, 19 months after complete remission under chemo + radiotherapy.

	Clinical presentation	Age /SEXE	LOCATION	ADMISSION PERIOD	TREATMENT	POST OPERATIVE COURSE
1	Diabetes insipidus	17 Months /F	Suprasellar /intraventricular	1999	-NTR through Trans ventricular approach. -VP shunt	Death in post-operative period
2	-Headache +vomiting -parinaud's syndrome -diplopia -decreased visual acuity	21Y/M	pineal	2000	-STR through sub occipital trans tentorial approach VP shunt for hydrocephalus -	-Radiotherapy - Death
3	-headache -vomiting -diabetes insipidus	20Y/M	Suprasellar /Pineal	2001	- VP shunt - Stereotaxic biopsy	-Radiotherapy -Survival without recurrence
4	-headache -vomiting -parinaud's syndrome	18Y/M	Pineal	1999	STR through sub occipital trans tentorial approach	-Radiotherapy -Survival without recurrence
5	-headache -vomiting -Diplopia -Papillar edema	17/M	Pineal	2005	VCS +biopsy	-Radiotherapy -Survival without recurrence
6	-headache -vomiting	33/M	Pineal	2006	VCS +biopsy	-RT -Survival without recurrence
7	-diabetes insipidus hemianopsia panhypopituitarism	20/M	Suprasellar /pineal	2013	STR trans lamina terminalis	RT+chT -Survival without recurrence
8	- headache -vomiting	24/M	Pineal	2014	-VP shunt STR through sub occipital trans tentorial approach	-RT -Survival without recurrence
9	diabetes insipidus panhypopituitarism	30Y/M	Suprasellar / Pineal	2014	STR Through intracerebellar approach	-death because of early post surgical complication
10	-diabetes insipidus -panhypopituitarism	34/M	-pineal -ventricular(VL,V3) (20 months before he had a only thickened pituitary stalk)	2014	STR trans ventricular approach	-RT -Survival without recurrence
11	-Pan hypopituitarism	19/M	-suprasellar (trigonoseptal , hypothalamic)	2018	Biopsy through transcallosal approach	-chT + RT Follow up at one year= no residue , march 2020 :recurrence and cervical metastases
12	- Pan hypopituitarism - epilepsy	16/M	Suprasellar/ pineal	2016	STR through pterional approach	death because of early post surgical complication
13	-aphasia -hemiplegia	42/M	Pineal / Ventricular	2013	Stereotaxic biopsy	-RT -Survival without recurrence

GTR: Gross-total resection, NTR: Near-total resection, STR: Subtotal resection, RT: Radiotherapy, ChT: Chemotherapy, F: Female, M: Male, VP shunt: ventriculoperitoneal shunt, , MRI: Magnetic resonance imaging.

DISCUSSION

The world health organization (WHO) divided germ cell tumors of the central nervous system into Benign and malignant tumors (germinomatous and non germinomatous tumor), Intracranial germ cell tumors represent 0.3% to 3.4% of all primary intracranial lesions [1].

Germinomas constitute about 65% of all intracranial GCT [1, 2]. Geographical and racial factors had been associated with higher incidence of CNS germ cell tumors in Asian countries like Japan, yet findings from large studies are inconsistent with prior reports [3]. The peak incidence of germinomas is in the second decade of life and it's more prevalent in male [1, 4, 3, 2, 5]. In our series, most the patients were males12 M/1F and the mean age of onset was 22 years (17 mounths – 42 years) and this age is close to reported mean age in the literature which is about 17 years.

PIGs typically affect brain midline regions such as suprasellar (25-35%), pineal (50-65%) and cerebellar vermis, basal ganglia and thalamus [1, 3, 4, 2, 6]. The intrasellar location Is Very rare [6]. Spinal cord metastases have been reported in 10% to 20% of patients [1]. In our series, one patient had cervical drop spinal cord metastasis.

PIGs generally occur in the suprasellar and pineal regions, and simultaneous occurrence in both regions is reported to comprise 8% of CNS germinomas cases [1, 3]. Suprasellar region is classical but rare and there is controversy regarding the synchronous or metastatic nature of the second location. Seven cases had a double location PIGS (suprasellar /pineal), while five patient's tumor was in the pineal region. One patient had a thickened pituitary stalk diagnosed when investigating diabetes insipidus for whom the follows up showed metastases of the tumor in the (VL, V3) twenty month later.

PIGs do not alter serum levels of ß-human chorionic gonadotropin (ß-hCG) and alpha-fetoprotein (AFP) [3]. In all our cases, histopathological examinations showed strong immunoreactivity for PLAP and C-kit (CD 117), with negative serum levels of ß-hCG and AFP.

Clinical presentation of PIGS patients depends on the location and the size of the lesion,in suprasellar masses, patients usually present with hypothalamic,or pituitary dysfunction causing isolated diabetes insipidus, or in association with other hormone deficiencies (puberty delay, growth failure ….) [3, 6]. In some cases, papilledema with restriction of upward gaze and convergent nystagmus on attempted upgaze (parinaud's syndrome) may be the presenting symptom, Ophthalmic abnormalities such as bilateral hemianopsia may also be present [1, 6].

The most common complaint in our series were diabetes insipidus and hormone deficiencies due to the frequent suprasellar location in our series.

The duration between the initial symptoms and time of surgical intervention ranged between 15days to 28 months.

Germinomas typically demonstrate increased attenuation relative to gray matter on CT related to the highly cellular lymphocyte component within the tumor. Lesions are typically isointense to hyperintense to gray matter on T1 and T2 weithed MRI, with cyst and necrotic changes seen in larger masses avid enhancement is seen following intravenous contrast administration. Some germinomas may histologically and radiologically masquerade as sarcoidosis or tuberculosis so that radiological characterization can be difficult. Reduced diffusion may be seen [6] due to its highly cellular nature, Hydrocephalus may be present, seven patients had hydrocephalus at the diagnostic moment in our series, MRI of the entire neuraxis and lumbar puncture is recommended to asses for CSF seeding and drop metastases [7, 4]. Germinomas and non germinomas tumors can't be distinguished based on radiographic findings [3].

The differential diagnosis for these lesions includes the primary pineal neoplasms, high-grade gliomas and lymphomas, craniopharyngiomas. However, if oncoproteins are present or engulfment of the pineal calcifications is found on CT scan, these findings can help narrow the differential diagnosis [7, 4]. granulomatosis and Langerhans cell histiocytosis (LCH) is a rare differential diagnosis. Yoon et al reported a case of bifocal tumor (pineal and suprasellar), that underwent chemotherapy + radiotherapy without histological confirmation followings some protocols that suggest to consider this entity of bifocal tumors, germionomas, because of their frequency without the need of biopsy, but in this case, the follows up showed an increase in the mass size, and the biopsy was finally in favor of LCH [3].

The management of primary CNS PIGS can vary but typically includes a multimodal treatment plan. Elevated serum and cerebrospinal fluid levels of tumor markers : beta human chronic gonadotropin(BHCG) and alpha foeto protein (AFP) in suspected germinomas tumors is indicative of secreting tumors, no further biopsy for histopathologic confirmation is required otherwise a biopsy is indicated for the non secreting germinomas (Mrad et al 2004) [3, 2, 8]. Packer et al suggested that biopsy proven germinomas can have non germinomatous elements among the unbiopsied site,in a similar way non secreting tumors can also have non germinomatous component such as immature teratomas with less favorable prognosis [1] GTR (gross total resection) may lead to the death by damaging midline structures. Subtotal resection (STR) or near total resection is recommended with leaving the part of the tumor attached to important neurovascular structures to confirm diagnosis and reduce the possibility of non germinomatous component residue [1, 8]. Advance in neuro endoscopy resulted in less aggressive procedure allowing to resolve the problem of hydrocephalus and perform the biopsy [3].

PIGS are particularly radiosensitive tumors [1, 4, 5], some authors described cases of regression of confirmed pigs after diagnostic radiation [9]. radiotherapy can later result in secondary malignancies or neurocognitive and neuro-endocrine sequelae such as decreased processing speed,working memory, and visual memory, it doesn't prevent the late development of recurrence and spinal cord metastases, Franzini et al,reported fatal recurrence in 15% of their Twenty patients [8]. Some oncology centers suggest a radiation dose of 50 gray, but these lesions can be used with doses less than 50 gray [1, 8, 10]. Reduced radiation dose and volume with localized germinomas without prophylactic use of craniospinal radiation, in association with chemotherapy is of particular importance, especially in pediatric patients,the results showed excellent progression free survival and less toxicity [3, 4, 8]. Chemotherapy alone without radiation has only proven ineffective resulting in increased relapse rate and worse outcomes [11]. Combined therapy of radiotherapy and chemotherapy is the treatment of choice for pigs [1, 8, 10]. Bifocal germinoma may be considered as disseminated disease when considering the patterns of failure according to radiotherapy fields [12].

CONCLUSION

Primary intracranial germinoma is a mostly malignant tumor that generally affects the children and young adult. It is a radiosensitive tumor, surgical management is still being important, since it allows histological confirmation, and reduce the possibility of the local recurrence and neuraxis dissemination when combined to radiotherapy + chemotherapy.

In the other hand gross-total resection is not a significant prognostic factor in outcome for patients with PIG, because of the complexity of the midline anatomy and the surgical related risk. Near total resection or subtotal resection is indicated to avoid the injury of the main neurovascular structures. Early diagnosis and the careful follow-up of these cases remain significant prognostic factors in the management of PIGS.

BIBLIOGRAPHIE

1. ABDALLAH A, ASILTURK M, UYSAL ML, EMEL E, ABDALLAH BG, BILGIC B, ET AL. Primary Intracranial Germinomas: Retrospective Analysis of Five Cases. Turk Neurosurg. 2018;28(1):29-35.
2. FRAPPAZ D, CONTER CF, SZATHMARI A, VALSIJEVIC A, MOTTOLESE C. The management of pineal tumors as a model for a multidisciplinary approach in neuro-oncology. Neurochirurgie. 1 avr 2015 ; 61 (2) : 208-11.
3. SEILANIAN TOOSI F, AMINZADEH B, FARAJI RAD M, NEKOOEI S, NAHIDI M. Pineal and Suprasellar Germinoma Cooccurence with Vertebra Plana : A Case Report. Brain Tumor Res Treat. oct 2018 6 (2) : 73-7.
4. REDDY MP, SAAD AF, DOUGHTY KE, ARMSTRONG D, MELGUIZO-GAVILANES I, ET AL. Intracranial germinoma. Proc (Bayl Univ Med Cent). janv 2015 ; 28(1) : 43-5.
5. MOTTOLESE C, SZATHMARI A, BEURIAT P-A. Incidence of pineal tumours. A review of the literature. Neurochirurgie. 1 avr 2015 ; 61 (2) : 65-9.

6. LAKHDAR F, HEMAMA M, LAGHMARI M, GANA R., MAAQILI R, BELLAKHDAR F. Double localisation d'un germinome cérébral. À propos d'un cas. Journal of Neuroradiology. 1 juill 2008 ; 35 : 177-80.

7. DEIANA G, MOTTOLESE C, HERMIER M, LOUIS-TISSERAND G, BERTHEZENE Y. Imagery of pineal tumors. Neurochirurgie. 1 avr 2015 ; 61 (2) : 113-22.

8. CALUGARU V, TAILLIBERT S, LANG P, SIMON J-M, DELATTRE J-Y, MAZERON J-J. Chimiothérapie néoadjuvante suivie d'une radiothérapie adaptée à la réponse tumorale dans les tumeurs germinales séminomateuses du système nerveux central: expérience de l'hôpital de la Pitié-Salpêtrière et revue de la littérature. Cancer/Radiothérapie. 1 mai 2007 ; 11 (3) 122-8.

9. WOO PYM, KAKAIZADA S, CHAN CCY, CHAN TSK, WONG H-T, CHAN K-Y. Diagnostic radiation-induced regression of a metastatic primary intracranial germinoma: a case report. Br J Neurosurg. 4 nov 2018;1-4.

10. SIFAT H, HADDADI K, EL GHAZI E, ERRIHANI H, KAMOUNI M, MANSOURI H, ET AL. Les germinomes du système nerveux central : étude rétrospective de six cas. Cancer/Radiothérapie. 1 sept 2002 ; 6 (5) : 273-7.

11. FETCKO K, DEY M. Primary Central Nervous System Germ Cell Tumors: A Review and Update. Med Res Arch. mars 2018 ; 6 (3).

12. CHUNG SY, HAN JW, KIM D-S, YOON HI, SUH C-O. Treatment outcomes based on radiation therapy fields for bifocal germinoma: Synchronous or disseminated disease? PLoS ONE. 2019 ; 14 (10) : e0223481.